



## Medtronic Freestyle Aortic Root Bioprosthesis Implantation for the Infective Endocarditis on Aortic Root

### Aortik Root İnfektif Endokarditinde Medtronic Freestyle Aortik Root Bioprotez İmplantasyonu

İnfektif Endokarditte Bioprotez İmplantasyonu / Bioprosthesis Implantation for the Infective Endocarditis

Zekeriya Arslan<sup>1</sup>, Murat Tavlaşoğlu<sup>2</sup>, Adem Güler<sup>3</sup>, Mehmet Ali Şahin<sup>2</sup>, Leyla Güler<sup>3</sup>

<sup>1</sup>Kardiyoloji AD. GATA, <sup>2</sup>Kalp Damar Cerrahisi AD., <sup>3</sup>Anestezi Reanimasyon AD. Gazi Üniversitesi Tıp Fakültesi, Ankara, Türkiye

#### Özet

İnfektif endokardit ve periannuler abse formasyonu, geniş cerrahi debridman ve aortik root replasmanı gerektiren ciddi bir kalp cerrahisi problemidir. Bu makalede başarılı bioprotez implantasyonu yaptığımız iki infektif endokardit vakasını sunacağız. Ekokardiyografik olarak tanı konulan biri prostetik diğeri nativ iki destrüktif aort kapak endokarditli hastada, konjestif kalp yetmezliği, NYHA klas-IV efor kapasitesi mevcuttu. Radikal cerrahi debridman uygulanan iki hastaya Medtronic Freestyle stentless aortik root bioprotez implante edildi. Antibiyotik tedavisi altı haftaya tamamlandı. Erken ve geç dönem mortalite olmadı. Bir hasta iki gün entübe kaldı ve A-V tam blok nedeniyle hastaya kalıcı pacemaker takıldı. On aylık takiplerinde bioprotez fonksiyonları normaldi ve endokardit bulgusu saptanmadı. Aort kapak ve root infektif endokardit tedavisinde Medtronic Freestyle stentless aortik root bioprotez, homogreftlerin çok iyi bir alternatifi olabilir.

#### Anahtar Kelimeler

Enfektif; Endokardit; Medtronic; Freestyle; Bioprotez

#### Abstract

Infective endocarditis and periannular abscess formation are serious problems in cardiac valve surgery, requiring extensive surgical debridement and reconstruction of the aortic annulus. We aimed to report two cases which were successfully treated with bioprosthetic valve implantation for infective endocarditis. Transesophageal echocardiography were performed for the diagnosis of one prosthetic and one native destructive aortic valve endocarditis in association with congestive heart failure (NYHA class-VI) and abscess formation. Medtronic Freestyle stentless aortic root bioprosthesis was implanted into the left ventricular outflow tract after surgical radical aortic root debridement for each patient followed with medical treatment, which was extended to six weeks. Neither early nor late mortality was detected. One patient required prolonged ventilatory support (two days) and permanent DDD-R pacing. Echocardiography showed no signs of valve dysfunction or recurrent endocarditis for both patients in 10 months follow up. Medtronic Freestyle stentless aortic root bioprosthesis may be a good alternative way of treatment to aortic valve and root endocarditis instead of homograft.

#### Keywords

Infective; Endocarditis; Medtronic; Freestyle; Bioprosthesis

DOI: 10.4328/JCAM.780

Received: 19.08.2011

Accepted: 14.09.2011

Printed: 01.05.2014

J Clin Anal Med 2014;5(3): 239-42

Corresponding Author: Adem Güler, Damar Cerrahisi AD., Ankara, Türkiye. T.: +90 3123041118 F.: +90 3123042020 E-Mail: aguler@gata.edu.tr

Introduction

Extensive surgical debridement is required in patients, who have annulus destruction, periannular abscess formation and fistulization in prosthetic or native aortic valve endocarditis. Surgical treatment is a lifesaving procedure, although its complications, morbidities and mortalities are high. There are different techniques in aortic root reconstruction, including fixing with autologous or bovine pericardium, aortic valve translocation, extra-anatomic bypass of aortic root, mechanical or stentless bioprosthetic valve replacement, homograft or valved conduit replacement with homograft or autograft.[1] Homografts are frequently preferred. Because, in addition to resistance to infections, flexibility preventing from tension and elasticity, homograft tissue fills the abscess cavity. Xenograft aortic root bioprosthesis are the most advisable alternative of homografts in centers where it is hard to find it. There have been several positive view recently published about resistance to infections, ten year durability, excellent hemodynamic accommodation of xenograft aortic root bioprosthesis. We will present Medtronic Freestyle bioprosthesis implantation in two infected endocarditis cases; first one was a prosthetic aortic valve endocarditis and second one was a native valve endocarditis, of which developed paravalvular abscess and whose annulus were destructed.

Case Report 1

A 22 year old male patient had recourse to cardiology department who was complaining of fever, weight loss (12 kg in a month), worsening of general physical condition, reflecting that his arthralgia began one month ago after he had upper respiratory tract infection. High degree of fever, sinus tachycardia, ¾ diastolic sufl heard at 3rd intercostal space were found in phsical examination. Functional capacity was NYHA class-IV. Severe aortic insufficiency and bicuspid aortic valve were demonstrated in transthoracic echocardiography. There was a mobile vegetation related to free edge of the both aortic cusps within the ventricle, moving forward and backward in each cardiac cycle. Same signs and paravalvular aortic root abscess were established at the transeosophageal echocardiography. Vancomycin sensitive non-hemolytic streptococcus were identified in the

blood culture. Patient was utilized vancomycin 2 gr/day, gentamicin 240 mg/day and rifampicin 600 mg/day while operation preparations were made. Aortic cannula for aortic cannulation and two-staged cannula for right atrial cannulation were used and pulmonary vent was settled via right pulmonary vein. Aorta was x-clamped and heart was arrested with antegrade cardioplegia and transvers aortotomy was performed. A 2x2 cm mobile vegetation was seen at the ventricular side of bicuspid aortic valve related to free edge of the both aortic cusps. Additionally, two paravalvular abscees were identified; first was between left atrial dome and aorta, second was between aorta and pulmonary artery. Debridement was performed for paravalvular abscess following aortic valve extraction and then necrotic tissue was completely removed. Abscess area was filled with a 3% formaldehyde absorbed tampons for three minutes to provide antibacterial effect and tissue stabilization. Right and left coronary artery ostiums were excised as button shape. Native pericardial tissue was placed like a stripe between bioprosthesis and aortic root to provide smooth area for settlement of bioprosthetic annulus. 27 mm Medronic Freestyle aortic root bioprosthesis was implanted to aortic annulus with 2/0 ethibond sutures one by one. Coronary buttons were implanted with using 5/0 polypropylene sutures and continue technique. Distal anastomosis between xenograft and aorta was achived with a 4/0 polypropylene suture and continue technique. We did not see cardiac block and his rhythm was sinus in ECG. We did not face to any problem in stopping CPB circuit. The histopathological examination of vegetation was found corresponding to infected endocarditis but there was no cultural propagation. A single dose of 300 mg aspirin was advised him for each day, and the antibiotic treatment was completed with six weeks and there was not any hemodynamic and clinical complication in post-operative period. The bioprosthesis was functionally normal in TEE, made postoperative 1st, 2nd, and 3rd month. Mean gradient over the aortic bioprothesis was 7 mmHg and no paravalvular leakage was determined at postoperative 4th month.

Case Report 2

21 years old male patient was undergone aortic root enlarge-

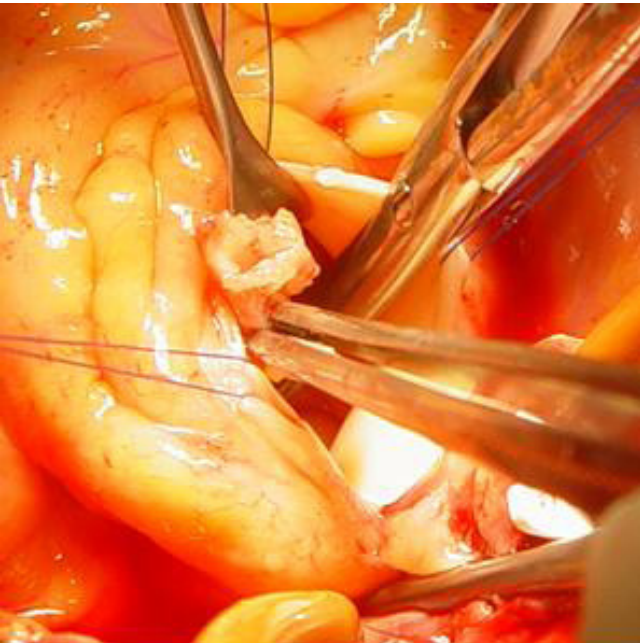

Figure 1. Aortic valve was exited, debritman was performed for paravalvular abscess and necrotic tissue was removed.

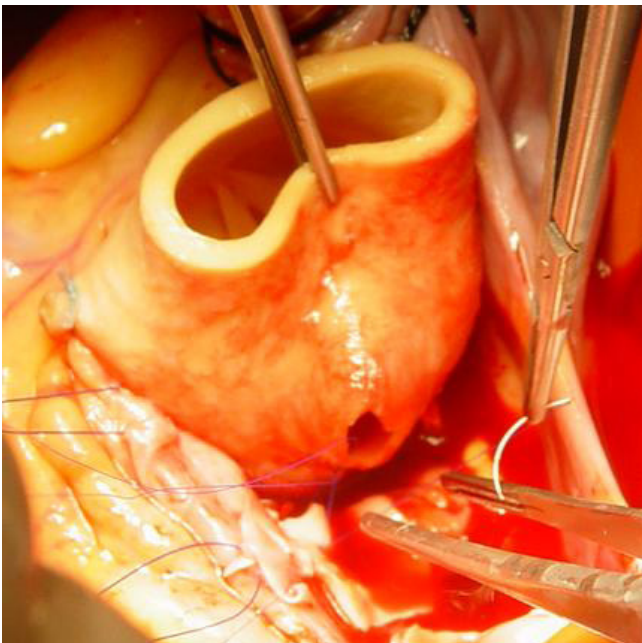


Figure 2. Medtronic Freestyle aortic root bioprosthesis was implanted and buttons of left and right coronary arteies were sutured to bioprosthesis.

ment with modified Manouguian's Technique and was implanted 21 mm mechanical aortic valve three months ago. He applied for cardiology department complaining of weakness, fatigue and high fever. A  $\frac{3}{4}$  diastolic sufl at 3rd intercostal space and high fever was present on physical examination. His functional capacity was NYHA class-IV. A dehiscence at the junction of mechanical valve and aortic annulus, two vegetations, and two abscess formations extending from aortic annulus to mitral anterior leaflet annulus were reported at TEE and TTE. The patient was admitted to operation urgently. After femoral cannulation had been made, sternotomy was performed and mediastinal adherence was removed. Right atrial cannulation was performed, vent was introduced via right superior pulmonary vein to left ventricle and retrograde cardioplegia cannule was introduced through right atrium. X-clamp was applied on aorta, cardiac arrest was achieved by antegrade and retrograde cardioplegia delivery. Aortotomy was made, a dehiscence was detected between the noncoronary cusp of aortic valve and mechanical prosthesis. An abscess was seen extending to the anterior leaflet of mitral valve. Left and right coronary artery buttons were prepared. Prosthetic valve and the patch material that was implanted previously in Manouguian's Technique were removed. The abscess was drained and the necrotic tissues at the annulus and subannular location were debrided. 23 mm Medtronic Freestyle aortic root bioprosthesis was implanted using 2/0 ethibond valv sutures and incorporating a pericardial stripe between the bioprosthesis and aortic annulus. Sutures were passed closer to mitral anterior leaflet annulus at the region of noncoronary cusp of aortic valve as a result of the tissue defect occurred after abscess debridement. After these procedures buttons of left and right coronary arteries were sutured to bioprosthesis as a continued fashion with 5/0 polypropylene sutures respectively. IABP support and positive inotropic drug administration had been initiated before CPB was stopped. Atrial and ventricular pacemaker wires were placed. Morphological signs of specimen which was taken in operation room corresponded to chronic inflammatory infiltration in histopathological examination and there was no propagation in bacteriologic examination in culture. Patient was observed in intensive care unit for seven days, and was left intubated for two days because of poor recovery of pulmonary functions. A-V block advanced to 3rd degree block and he was taken care of for a while with his A-V pace wire. After the patient was advised permanent pacemaker implantation, DDD pacemaker was implanted. In the follow up period there was no complaint; a single dose of 300 mg aspirin was advised him for each day following six weeks antibiotic treatment. The bioprosthesis was functionally normal in TEE, made postoperatively 1st, 2nd, 3rd week. Mean gradient over the aortic bioprosthesis was 6 mmHg and no insufficiency was determined at postoperative 8th month.

## Discussion

Although the patients with mechanical prosthetic valves have the excellent long term performance and low reoperation rate, they are thrombogenic and they need lifelong anticoagulant therapy. Applicability of greater size in patients with small aortic roots, lower mean gradients of the valves, quicker regression of left ventricular hypertrophy after implantation, lower antigenic material content, applicability in patients with infective endocarditis because of more resistance to infections, lower thrombogenicity and no need for anticoagulation has popularized the use of new generation stentless bioprosthesis.

Despite of the 20% mortality rate in native valve endocarditis, short term mortality rate might be as high as 80% in prosthetic valve endocarditis.[2] Aortic annulus destruction and abscess formation increases the morbidity and mortality. Hemodynamic impairment due to heart failure, intracardiac fistula and the risk of cerebral embolus required to aggressive medical and surgical management. In the management of active aortic root endocarditis with periannular abscess formation, urgent aggressive surgical management yields better results than delayed surgery. [3] The complete resection of the infected and necrotic tissues facilitates the control of focal infection, prolongs the survival and minimizes the risk of recurrent endocarditis. We also believe that aggressive surgical management is more effective.

Stentless porcine aortic valve have the same design as aortic homograft in having minimum non-biological content. Medtronic Freestyle aortic root bioprosthesis is a complete porcine aortic root, in which coronary ostia are ligated, fixated by glutaraldehyde and treated with an antiminerallising agent (alfaaminooleic acid). It is less flexible and less pliable than fresh or cryopreserved allograft. Medtronic Freestyle bioprosthesis has many advantages over traditional bioprosthesis; hemodynamic compatibility, laminar flow pattern, resistance to calcification, and durability.[4] No problem was noted during the follow up period of our patients.

An ideal stentless aortic valve for a person is own pulmonary valve. The flow characteristic and durability of the pulmonary valve is excellent when it is used in the aortic position. However Ross Procedure increases operative risk because it includes two root operations for replacement of a single valve. Aortic homografts weren't used routinely because of limited availability, despite their excellent hemodynamic performance.

Kon and colleagues reported 100% free from structural valve deterioration 96.9% free from post-operative endocarditis, and 83.3% free from thromboembolic complications in their eight year experience with Medtronic Freestyle aortic root bioprosthesis implantation in 104 patients.[5] The angle between the right and left coronary ostia is 120-160° in humans and it is 90-120° in porcine aortic root. It was also reported that the hardness in implanting the human coronary ostia to porcine aortic root can be overcome by rotating the bioprosthesis 120° right, and implanting the porcine non-coronary sinus to left coronary sinus and porcine left coronary sinus to right coronary sinus. We also had hardness in reimplanting the right coronary button to right coronary ostia of the bioprosthesis; because right coronary button was not suitable for the right coronary ostia of the bioprosthesis, so we solved the problem by pinching a more proximal hole to the bioprosthesis nearer to annulus for implantation of right coronary button. But the editor suggested the 120° rotation of bioprosthesis in this situation and recommended this method.

Bach and colleagues reported the results of 725 cases with aortic valve disease and Medtronic Freestyle aortic root bioprosthesis implantation, the freedom from structural valve deterioration was 96%, the freedom from reoperation was 92%, the freedom from post operative aortic regurgitation was 98% and the freedom from thromboembolic complications was 83.3% in ten patients.[6] These results are better than other types of bioprosthesis. Structural deterioration due to calcification was noted only in three patients. During the same study, the bioprosthesis were implanted in three different techniques which are subcoronary anastomosis, root inclusion and total root replacement. Best results were observed in total root replacement

technique. We also used this technique to cover the infected tissues completely.

Muller and colleagues reported 10 cases with destructive aortic valve endocarditis and with abscess formation which was treated by Medtronic Freestyle stentless bioprosthesis implantation instead of aortic homograft. The excellent surgical results and no recurrence of endocarditis after 42 months of follow up were reported in these patients. The authors suggested the Medtronic Freestyle aortic bioprosthesis whenever indicated or in patients over 60 years. If suitable homograft cannot be found or in emergent cases, it might be a lifesaving treatment in younger patients.[1] Both of our patients were young; but we had to use xenografts since no any allograft was available.

In Kosuyolu Hospital experience with five patients, no recurrence of infections were noted during six months of follow up.[3] They used xenografts in emergency patients instead of homografts which had similar performance, better availability and near excellent long term results. Fukui and colleagues reported five cases with aortic root infection and underwent aortic root replacement with Medtronic Freestyle stentless bioprosthesis, with no early and late mortality and no recurrence of infection. Three of those five patients had prosthetic valve endocarditis.[7]

Medtronic Freestyle aortic root bioprosthesis is a lifesaving choice in the treatment of aortic root endocarditis especially in countries like ours, where aortic homografts are not widely available. It is the valve type of choice in the surgical treatment of destructive aortic root endocarditis because of its wide availability, minimal non biologic content, anatomy like native aorta, excellent geometrical compatibility, optimum hemodynamical performance, no hemodynamic and structural deterioration in 10 year results and low rate of infectious complications.

### Competing interests

The authors declare that they have no competing interests.

### References

1. Müller LC, Chevtchik O, Bonatti JO, Müller S, Fille M, Laufter G. Treatment of destructive aortic valve endocarditis. *Ann Thorac Surg* 2003;75(2):453-6.
2. Xiao-Fang Xu and Mark Murphy. Infective endocarditis. *Manuel of Cardiovascular Medicine*. 2.edition. Brian P. Griffin, Eric J. Topol. Philadelphia 2004. p.250-265.
3. Bozbuğa N, Erentuğ V, Erdoğan HB, Kırallı K, Ardal H, Tas S et al. Surgical treatment of aortic abscess and fistula. *Tex Heart Ins J* 2004;31(4):382-6.
4. Akar R, Szafrank A, Alexiou C, Janas R, Janinski MJ, Swanevelde J et al. Use of stentless xenografts in the aortic position: determinants of early and late outcome. *Ann Thorac Surg* 2002;74(5):1450-8.
5. Kon ND, Riley RD, Adair SM, Kitzman DW, Cordell AR. Eight-year results of aortic root replacement with the freestyle stentless porcine aortic root bioprosthesis. *Ann Thorac Surg* 2002;73(6):1817-21.
6. Bach DS, Kon ND, Dumesnil JG, Sintek CF, Doty DB. Ten-year outcome after aortic valve replacement with the freestyle stentless bioprosthesis. *Ann Thorac Surg* 2005;80(2):480-6.
7. Fukui T, Suehiro S, Shibata T, Hattori K, Hirai H, Aoyama T. Aortic root replacement with freestyle stentless valve for complex aortic root infection. *J Thorac Cardiovasc Surg* 2003;125(1):200-3.